WHO Grade III Anaplastic Ependymoma of the Filum Terminale with Cerebral Metastasis: A Case Report

Chahrazad ZAIR, Sara DELLALDJA, Anis KRAOUN, Lynda ATROUNE

Department of Neurosurgery, Ali Aït Idir Specialized Hospital, Algiers.

Received: 04 September 2026 *Accepted: 29 October 2026* *Published: 15 November 2026*

Citation: Chahrazad ZAIR, Sara DELLALDJA, Anis KRAOUN, Lynda ATROUNE. WHO Grade III Anaplastic Ependymoma of the Filum Terminale with Cerebral Metastasis: A Case Report. ***JMSP Vol. 2, Issue 2, 2026****, pp. 64–73.*

Abstract

Grade III anaplastic ependymoma of the filum terminale is exceptional: this region is dominated by the myxopapillary subtype, and only 21 to 24 cases of anaplastic transformation have been reported.

Case summary: A 36-year-old patient presented with a two-month progressive conus medullaris syndrome with early sphincter disturbances. MRI showed an intradural extramedullary lesion at D11–D12, heterogeneously enhancing, compressing the conus and cauda equina roots. Histopathological examination of the specimen resected via D10–L1 spinolaminectomy established the diagnosis of a grade III anaplastic ependymoma arising from the filum terminale.

During adjuvant radiotherapy, headaches and vomiting from the 12th session preceded, at the 26th session, generalized tonic-clonic seizures with altered consciousness. Stage 2 papilledema and, on contrast-enhanced CT, hypothalamic-pituitary enhancement (leptomeningeal dissemination) with triventricular hydrocephalus led to emergency ventriculoperitoneal shunting, followed by marked improvement.

Discussion: This case combines a triple discordance (topographic, radiological, histological) and secondary intracranial dissemination, adding an intracranial dimension to a spinal disease.

Conclusion: The true grade is established only by pathology. Headaches and vomiting during radiotherapy warrant early cerebral imaging rather than attribution to toxicity.

1. Introduction

The conus medullaris, filum terminale, and cauda equina constitute an anatomical transition zone in which a varied histological spectrum of primary tumors develops. Myxopapillary ependymoma overwhelmingly dominates this spectrum, accounting for up to 90% of tumors in this region (1,2), followed by schwannoma, the second most frequent type, arising from the cauda equina roots (3). Astrocytoma shares with ependymoma the leading position among tumors intrinsic to the conus medullaris (4), while rarer entities may also be encountered here: paraganglioma/neuroendocrine tumor of the cauda equina, metastases via leptomeningeal dissemination, and, exceptionally, glioblastoma (5,6). Within this spectrum, grade III (anaplastic) ependymoma occupies a distinct position owing to its extreme rarity: in a tertiary-center study dedicated specifically to tumors of the conus and filum, it accounted for only 6% of cases (2 of 31), compared with 55% myxopapillary and 39% classic grade II tumors (7). This rarity is confirmed at the level of the world literature, where secondary anaplastic transformation of a pre-existing myxopapillary ependymoma

totals only 21 to 24 reported cases, of which only 5 have histological confirmation of malignant transformation at recurrence (8,9), and where intradural extramedullary presentation, across all histological subtypes, does not exceed 24 cases published to date (10,11). It is this dual rarity — of location and of grade — that confers particular interest on our observation of grade III anaplastic ependymoma of the conus medullaris, justifying its presentation in light of the existing literature.

2. Case Presentation

2.1 History and Clinical Presentation

We report the case of a 36-year-old patient with no notable medical history, presenting over the preceding two months with a progressively worsening conus medullaris syndrome, comprising: a spinal syndrome (back pain, positive bell sign at D11–D12), a conus medullaris syndrome (sensory level below the right umbilicus at D12, absent lower abdominal reflexes on the right, bilateral alternating radicular pain in the lower limbs, and diffuse, poorly systematized paresthesia, spastic paraparesis graded 1/5 on the left and 3/5 on the right, absent deep tendon reflexes, indifferent plantar reflex), and early sphincter disturbances (urinary retention, saddle hypoesthesia, constipation).

2.2 Imaging

Dorsolumbar MRI demonstrated an intradural extramedullary lesion extending from D11 to D12, left-sided, with irregular margins, isointense on T1-weighted and heterogeneously hyperintense on T2-weighted sequences, showing heterogeneous contrast enhancement after gadolinium administration, occupying the width of the spinal canal from front to back.

The lesion displaced and compressed the conus medullaris toward the right, as well as the cauda equina roots, which were displaced and fanned out against the dura anteriorly and to the right, reflecting significant compression of these structures.

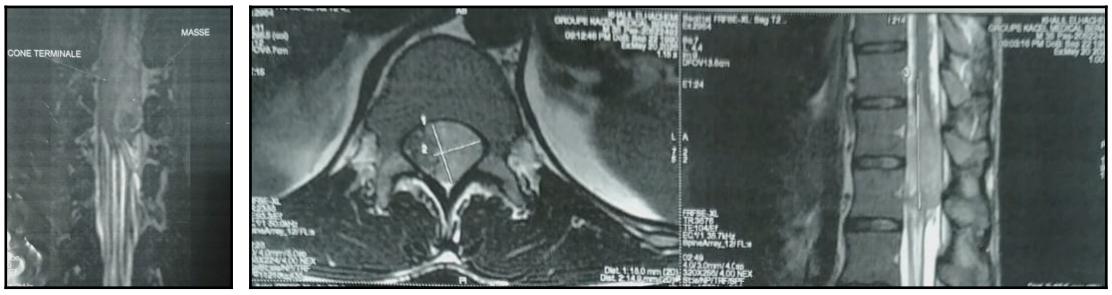

Figure 1: Preoperative dorsolumbar MRI (20 May 2026). Left, localization of the conus medullaris and the mass; right, axial and sagittal T2-weighted images showing the intradural extramedullary lesion at D11–D12.

2.3 Surgical Management

The patient underwent surgical resection via a posterior approach, in the prone position, by D10–L1 spinolaminectomy with preservation of the facet joint line. On dural opening, the tumor, which was red and hemorrhagic, herniated outward, necessitating initial debulking before dissection of its poles and tumor evacuation from the periphery inward, with careful dissection of the cauda equina roots, which were adherent to the spinal cord in a setting of local arachnoiditis. At the end of the dissection, the tumor's insertion into the filum terminale was identified.

2.4 Histopathology

Histological examination of the resected specimen revealed a glial neoplastic proliferation of low to moderate cellular density, composed of astrocyte-like cells with minimal to focally marked cytonuclear atypia, increased vascularity with glomeruloid endothelial proliferation, and necrotic changes. Immunohistochemistry showed cytoplasmic positivity for GFAP, a Ki-67 index of 8%, and heterogeneous EMA positivity, leading to a diagnosis of grade III anaplastic ependymoma.

2.5 Postoperative Course and Adjuvant Treatment

The patient was referred for adjuvant radiotherapy, which was started one month after surgery. After the 12th session, he developed headaches and vomiting, attributed to side effects of the radiotherapy. By the 26th session, he presented with seizures, and the clinical picture worsened with an altered level of consciousness; he was confused and disoriented.

Craniospinal MRI showed triventricular dilatation without obstruction, with the third ventricle measuring 12 mm and symmetrical dilatation of the lateral ventricles; the fourth ventricle was not dilated. Spinal imaging showed persistent residual tumor measuring 20 × 16 × 11 mm at the conus medullaris on the left.



Figure 2: Postoperative MRI (4 July 2026, then 7 September 2026): axial T2-weighted brain images showing triventricular dilatation, and T1-weighted spinal images showing the residual tumor at the conus medullaris, with measurements.

Enhancement of the lumbar soft tissues facing D11 and D12 and a discrete hyperintensity of the D11–D12 vertebral bodies were attributed to radiotherapy, with no suspicious bone lesion detectable. The conclusion of the examination was persistence of a spinal residual tumor and triventricular hydrocephalus without any unfavorable lesion of the cerebral parenchyma or cervical cord.

Ophthalmological examination revealed decreased visual acuity in both eyes with stage 2 papilledema on fundoscopy.

Brain CT, performed before and after contrast administration before shunt placement, showed thickening of the upper part of the pituitary stalk and of the hypothalamus,

with contrast enhancement, in contact with the posterior surface of the chiasm and forming the floor of the third ventricle, with triventricular dilatation involving the lateral ventricles and the third ventricle (10 mm in transverse diameter).

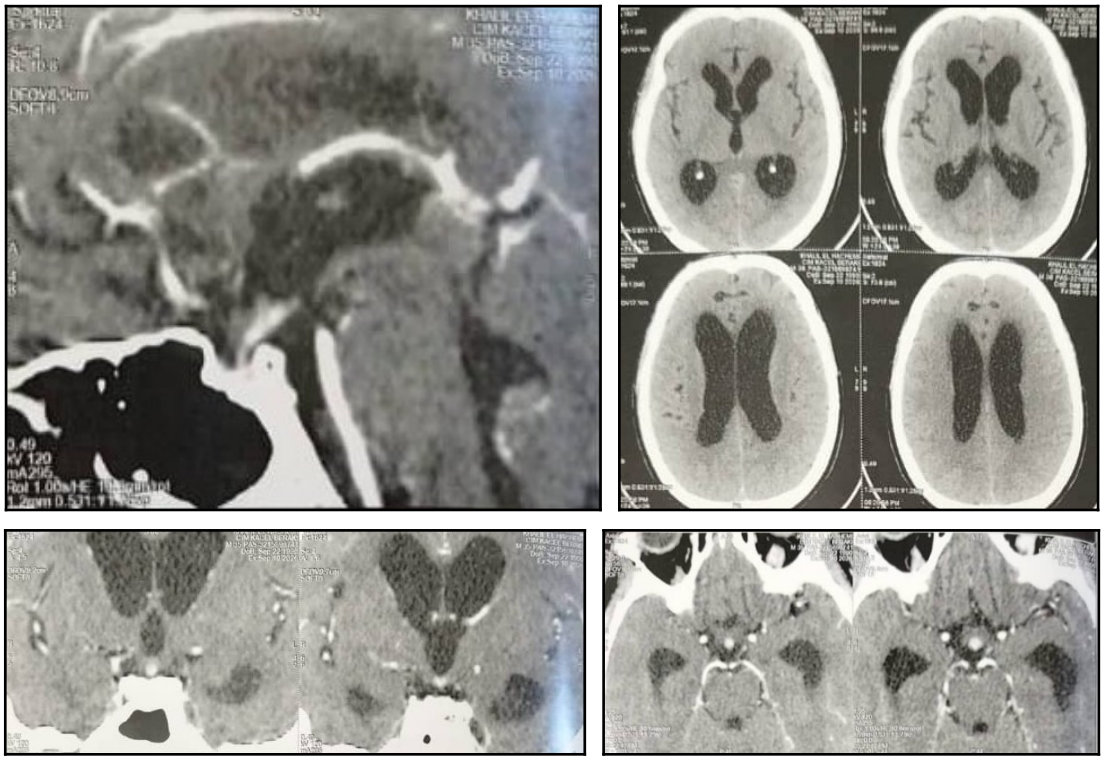

Figure 3: Contrast-enhanced brain CT before shunting (10 September 2026): triventricular hydrocephalus and enhancement of the hypothalamus and pituitary stalk (axial images, coronal and sagittal reconstructions).

The conclusion was pathological enhancement of the hypothalamus and proximal pituitary stalk, to be considered as leptomeningeal dissemination of the spinal tumor, with triventricular hydrocephalus.

No obstruction was visualized as the cause of this hydrocephalus, which occurred well after the surgical resection, and no CSF study was performed. The patient underwent emergency ventriculoperitoneal (VP) shunt placement.

Marked clinical improvement was noted, with disappearance of the signs of intracranial hypertension and return to a normal level of consciousness.

The case was discussed at a multidisciplinary tumor board and then referred to oncology for adjuvant radiotherapy and to endocrinology for follow-up to monitor for any hormonal disturbances that might occur during the course of the disease.

3. Discussion

Ependymoma is a slow-growing glial tumor arising from the ependymal cells lining the central canal of the spinal cord, accounting for 45% of intraspinal tumors and 4–6% of primary tumors of the central nervous system (1,2). At the level of the conus medullaris and filum terminale, the overwhelming majority of these tumors correspond to the myxopapillary subtype, which alone is reported to account for up to 90% of tumors in this region, whereas non-myxopapillary forms account for only approximately 30% of cases (3,4). In a tertiary-center study dedicated specifically to ependymomas of the conus and filum, only 6% of cases (2 of 31) corresponded to

grade III anaplastic ependymoma, compared with 55% myxopapillary and 39% classic grade II tumors (5). Secondary anaplastic transformation of a pre-existing myxopapillary ependymoma likewise remains exceptional, with only 21 to 24 cases reported in the world literature and 5 cases of confirmed malignant transformation at recurrence (6,7). Finally, intradural extramedullary presentation, across all histological subtypes, accounts for no more than 24 published cases to date (8,9). This rarity, consistent across every subcategory considered, underscores the exceptional nature of grade III anaplastic ependymoma of the conus medullaris and justifies the interest of reporting the present observation.

This rarity is compounded by a diagnostic difficulty well recognized in the literature. Montoya et al. (10) emphasize that, to date, no pathognomonic clinical or radiological feature allows the anaplastic nature of an ependymoma to be established before definitive histological analysis. Clinical presentation depends essentially on the site of the lesion (pain or myelopathic syndrome) rather than on its grade. On MRI, these tumors typically present as well-circumscribed, encapsulated intradural masses enhancing after gadolinium administration, without dural attachment — although cases of arachnoid infiltration and an intrinsic vascular component have been reported, sometimes rendering the differential diagnosis with schwannoma, meningioma, neurofibroma, or paraganglioma difficult, as all of these may likewise present as intradural extramedullary tumors (10). The same authors note that, to date, no clearly established therapeutic consensus exists for high-grade ependymomas, although macroscopically complete resection combined with adjuvant radiotherapy is generally recommended, recurrence most often occurring through CSF dissemination to another spinal level or to the brain (10). In the largest series published to date, comprising 20 consecutive cases of primary spinal anaplastic ependymoma, a cervical and thoracic predominance was noted, clinical presentation remained nonspecific, and contrast enhancement was often heterogeneous, making the distinction from classic grade II ependymoma difficult even on imaging; surgery was reported as the first-line treatment, while the role of radio-chemotherapy remained poorly defined (10,11). Cervical location has additionally been associated with a less favorable prognosis in another series (12).

Our observation is notable for a tumor originating from the filum terminale — a location classically associated with myxopapillary ependymoma (5,6) — even though definitive histological analysis established a diagnosis of grade III anaplastic ependymoma, in contradiction with the histological profile usually expected at this level. This discordance between the site of origin, strongly suggestive of a low-grade tumor, and the histological grade actually found, constitutes one of the most original features of our case, and echoes the diagnostic difficulties already emphasized by Montoya et al. (10), who note that no clinical, radiological, or even, at times, intraoperative finding allows the true grade of an ependymoma arising at this level to be predicted with certainty before pathological confirmation. Combined with the initial radiological discordance favoring a schwannoma, this observation thus illustrates a triple discordance — topographic, radiological, and histological — reinforcing the interest of its publication.

The subsequent course of our patient further distinguishes this case. Radiotherapy, started one month after surgery, was followed by headaches and vomiting from the 12th session onward — initially attributed to treatment side effects — and, by the 26th session, by seizures with altered consciousness in the setting of triventricular hydrocephalus, associated with stage 2 papilledema and decreased visual acuity and

with pathological enhancement of the hypothalamus and proximal pituitary stalk on contrast-enhanced brain CT, requiring emergency ventriculoperitoneal shunting, followed by marked clinical improvement (disappearance of the signs of intracranial hypertension and return to a normal level of consciousness).

Hydrocephalus is an uncommon association of spinal tumors, documented in case reports and small series, including spinal ependymomas and other spinal cord tumors (17,19). The mechanisms proposed include impaired CSF absorption at the arachnoid villi related to markedly elevated CSF protein, disturbance of CSF dynamics by the tumor itself, and obstruction of CSF pathways, notably by disseminated tumor cells (17,19).

In the present case, the anaplastic histology — with its recognized risk of CSF dissemination to other spinal levels or to the brain (10) — together with the pathological enhancement of the hypothalamus and proximal pituitary stalk, interpreted on CT as leptomeningeal dissemination of the spinal tumor, makes tumor dissemination within the CSF pathways the favored hypothesis; the initial craniospinal MRI had detected neither parenchymal lesion nor pathological enhancement, which underlines that early dissemination may be difficult to detect, since microscopic or sub-radiological involvement may suffice to impede CSF circulation or absorption. Retrograde intracranial dissemination of a spinal ependymoma, although infrequent, has been reported as a cause of hydrocephalus (17,18); as in the case reported by Benomar et al., hydrocephalus was associated in our patient with radiologically visible intracranial leptomeningeal involvement (18), and the importance of imaging the entire neuraxis has been emphasized (18).

The triventricular hydrocephalus of our patient occurred well after the surgical resection and without any visualized obstruction, which renders an early postoperative mechanism less plausible and reinforces the hypothesis of tumor dissemination within the CSF pathways. As no CSF study was available in our patient, the interpretation of dissemination remains radiological: CSF cytology — recommended by EANO for postoperative staging (16) — would have been the most useful examination to confirm it, and its value is underlined here.

Regarding adjuvant radiotherapy, the EANO recommends postoperative irradiation of 45–54 Gy for anaplastic (WHO grade III) spinal ependymoma regardless of the extent of resection (class of evidence III, level of recommendation C), after staging that includes craniospinal MRI and CSF cytology performed no earlier than 2–3 weeks after surgery (16). The usual regimen combines conventional fractionation of 1.8 Gy per fraction, delivered by conformal or intensity-modulated radiotherapy, to a local volume encompassing the surgical bed and residual tumor with a craniocaudal margin of 1–2 cm; the dose is limited by spinal cord tolerance (myelopathy risk of approximately 0.2% at 50 Gy and 6% at 60 Gy in 2-Gy equivalents), although doses up to 59.4 Gy may be considered below the conus medullaris (21,22). In cases of documented CSF or spinal dissemination, craniospinal irradiation of 36 Gy with a boost of 45–54 Gy to focal lesions is proposed (expert consensus formulated for adult intracranial ependymomas) (16). In our case, the leptomeningeal dissemination suspected on imaging argues for considering craniospinal irradiation, the indication for which remains to be confirmed by CSF cytology and follow-up MRI.

Three practical points emerge. First, the early headaches and vomiting attributed to radiotherapy may in retrospect have been early manifestations of raised intracranial pressure, as later evidenced by stage 2 papilledema with decreased visual acuity; in a

patient with a high-grade spinal ependymoma, such symptoms arising during treatment warrant prompt cerebral imaging and fundoscopy rather than an assumption of treatment toxicity. Second, the persistent 20 × 16 × 11 mm residual tumor at the conus medullaris indicates that the macroscopically complete resection generally recommended (10) was not achieved, which underlines the value of adjuvant radiotherapy and of close clinical and radiological surveillance. Third, CSF diversion in the presence of a spinal tumor carries a recognized risk of neurological deterioration through upward spinal coning (20); in our patient, shunting occurred well after an incomplete spinal resection, which warrants careful neurological monitoring after shunting, while the hydrocephalus itself required emergency management. The combination of an anaplastic ependymoma arising from the filum terminale and symptomatic hydrocephalus arising during adjuvant radiotherapy, with hypothalamic and pituitary stalk leptomeningeal dissemination and on a background of residual spinal tumor, renders the present observation still more unusual, and supports systematic craniospinal surveillance in this setting.

4. Conclusion

Grade III anaplastic ependymoma of the filum terminale remains an exceptionally rare entity, and our observation illustrates its characteristic diagnostic difficulty: a nonspecific clinical presentation as a conus medullaris syndrome, imaging initially suggestive of a schwannoma, and a definitive diagnosis relying exclusively on pathological and immunohistochemical analysis (GFAP+, Ki-67 8%, glomeruloid endothelial proliferation, necrosis). This topographic, radiological, and histological discordance highlights the fact that no preoperative finding currently allows the true grade of a tumor arising at this level to be predicted with certainty, and underscores the importance of systematic histological confirmation, regardless of the initial diagnostic presumption. The subsequent occurrence, during adjuvant radiotherapy, of triventricular hydrocephalus with papilledema, associated with hypothalamic and pituitary stalk enhancement interpreted as leptomeningeal dissemination of the spinal tumor and requiring emergency ventriculoperitoneal shunting further underscores the potential for intracranial complications, and the need to investigate promptly, with craniospinal imaging, any headache, vomiting, seizure, or alteration of consciousness arising during treatment. Given the aggressive nature of this variant, the persistent residual tumor at the conus medullaris, and the risk of local recurrence or leptomeningeal dissemination described in the literature, close clinical and radiological surveillance, combined with appropriately tailored adjuvant management, appears essential. Through its extreme rarity, this case thus contributes to the existing literature on anaplastic ependymoma of the conus medullaris and calls for diagnostic vigilance when faced with any intradural extramedullary mass in this region, even in the presence of reassuring radiological features.

Beyond conventional histological classification, molecular biology is playing an increasingly important role in the characterization of high-grade ependymomas. The 2021 WHO classification of central nervous system tumors (CNS5) introduced, for the first time, a molecularly defined entity specific to spinal ependymomas: spinal ependymoma with MYCN amplification, characterized by a distinct methylation profile and a particularly aggressive clinical course, with a median progression-free survival of only 17 months (13,14). Several authors now emphasize that prognostic stratification based on the molecular and epigenetic (methylome) profile outperforms histological grading alone, which may even be misleading for certain molecularly high-risk subgroups misclassified as grade II (13). Although no targeted therapy has

yet been validated for MYCN amplification, several approaches are currently under preclinical evaluation, including inhibition of HDAC, PARP, AURKA, and BET proteins, as well as immunotherapeutic strategies (15). These advances argue for complementary molecular characterization (assessment of MYCN amplification, methylation profiling) of anaplastic ependymomas at atypical locations such as ours, which may in the future refine prognosis, guide surveillance, and pave the way for targeted therapies tailored to this rare, poor-prognosis subgroup.

References

1. Kim BS, Kim SW, Kwak KW, Choi JH. Extra and intramedullary anaplastic ependymoma in thoracic spinal cord. *Korean J Spine*. 2013;10(3):177-180.

2. Cerase A, Venturi C, Oliveri G, De Falco D, Miracco C. Intradural extramedullary spinal anaplastic ependymoma. Case illustration. *J Neurosurg Spine*. 2006;5(5):476.

3. Oke ET, Nnamani E, Abualsaud S, Nnamani U. Spinal Myxopapillary Ependymoma Presenting With Isolated Intracranial Hypertension: A Case Report. *Cureus*. 2025;17(7):e87616.

4. Trivedi R, Trivedi P. Multisegment Intradural Extramedullary Ependymoma. *Cureus*. 2021;13(12):e20329.

5. Sudhan MD, Satyarthee GD, Joseph L, Sharma MC, Kakkar A, Sharma BS. Management and Outcome Analysis of Conus and Filum ependymoma: A Tertiary Center Study. *Asian J Neurosurg*. 2019;14(3):821-827.

6. Khristov V, Shenoy G, Mau C, Mrowczynski O, Rizk E, Pu C, Specht CS, Aregawi D. Myxopapillary Ependymoma with Anaplastic Features: A Case Series and Review of the Literature. *World Neurosurg*. 2022;158:e735-e745.

7. Kanno H, Kanetsuna Y, Shinonaga M. Anaplastic myxopapillary ependymoma: A case report and review of literature. *World J Clin Oncol*. 2021;12(11):1072-1082.

8. Guppy KH, Hou L, Moes GS, Sahrakar K. Spinal intradural, extramedullary anaplastic ependymoma with an extradural component: Case report and review of the literature. *Surg Neurol Int*. 2011;2:119.

9. Chakravorty A, Frydenberg E, Shein TT, Ly J, Earls P, et al. Multifocal intradural extramedullary anaplastic ependymoma of the spine. *J Spine Surg*. 2017;3:727-731.

10. Montoya F, Restrepo C, Rojas LO, Donato A, Velandia JF. Anaplastic ependymoma of the filum terminale "A case Report and review of the literature". *Neuro Neurosurg*. 2019;2. DOI: 10.15761/NNS.1000121.

11. Liu X, Sun B, Xu Q, Che X, Hu J, et al. Outcomes in treatment for primary spinal anaplastic ependymomas: a retrospective series of 20 patients. *J Neurosurg Spine*. 2013;19:3-11.

12. Prayson RA, Cohen ML, Kleinschmidt-DeMasters B. Anaplastic ependymoma, in David EE (ed): *Brain Tumors (Consultant Pathology)*. New York: Demos Medical Pub. 2010:80-83.

13. Kresbach C, Neyazi S, Schüller U. Updates in the classification of ependymal neoplasms: the 2021 WHO Classification and beyond. *Brain Pathol*. 2022;32(4):e13068.

14. Swanson AA, Raghunathan A, Jenkins RB, Messing-Jünger M, Pietsch T, Clarke MJ, Kaufmann TJ, Giannini C. Spinal Cord Ependymomas With MYCN Amplification Show Aggressive Clinical Behavior. *J Neuropathol Exp Neurol*. 2019;78(9):791-797.

15. Cerretti G, Pessina F, Franceschi E, Barresi V, Salvalaggio A, Padovan M, et al. Spinal ependymoma in adults: from molecular advances to new treatment perspectives. *Front Oncol*. 2023;13:1301179.

16. Rudà R, Reifenberger G, Frappaz D, Pfister SM, Laprie A, Santarius T, et al. EANO guidelines for the diagnosis and treatment of ependymal tumors. *Neuro Oncol*. 2018;20(4):445-456. doi:10.1093/neuonc/nox166.

17. Kordás M, Czirják S, Dóczi T. The spinal tumour related hydrocephalus. *Acta Neurochir (Wien)*. 1997;139(11):1049-1054.

18. Benomar A, Khellaf A, Kadi L, Ferreira J, Lavergne P, Bergeron F, Laroche M. Giant metastatic mixed-type spinal ependymoma presenting with hydrocephalus. *Radiol Case Rep*. 2024;19(11):4751-4754. doi:10.1016/j.radcr.2024.07.127.

19. Rifkinson-Mann S, Wisoff JH, Epstein F. The association of hydrocephalus with intramedullary spinal cord tumors: a series of 25 patients. *Neurosurgery*. 1990;27:749-754.

20. Jooma R, Hayward RD. Upward spinal coning: impaction of occult spinal tumours following relief of hydrocephalus. *J Neurol Neurosurg Psychiatry*. 1984;47:386-390.

21. Bodensohn R, Haehl E, Belka C, Niyazi M. Fractionated radiotherapy for spinal tumors: a literature review regarding spinal glioma, ependymoma, and meningioma. *Neuro Oncol Adv*. 2024;6(Suppl 3):iii101-iii109. doi:10.1093/noajnl/vdad158.

22. Kirkpatrick JP, van der Kogel AJ, Schultheiss TE. Radiation dose-volume effects in the spinal cord. *Int J Radiat Oncol Biol Phys*. 2010;76(3 Suppl):S42-S49.